



Central precocious puberty : A case-report

DR. MAHTAB ORDOOEI

PEDIATRIC ENDOCRINOLOGIST

ASSOCIATE PROFESSOR OF PEDIATRIC ENDOCRINOLOGY & METABOLISMA SHAHID SADOGHY YAZD UNIVER SITY

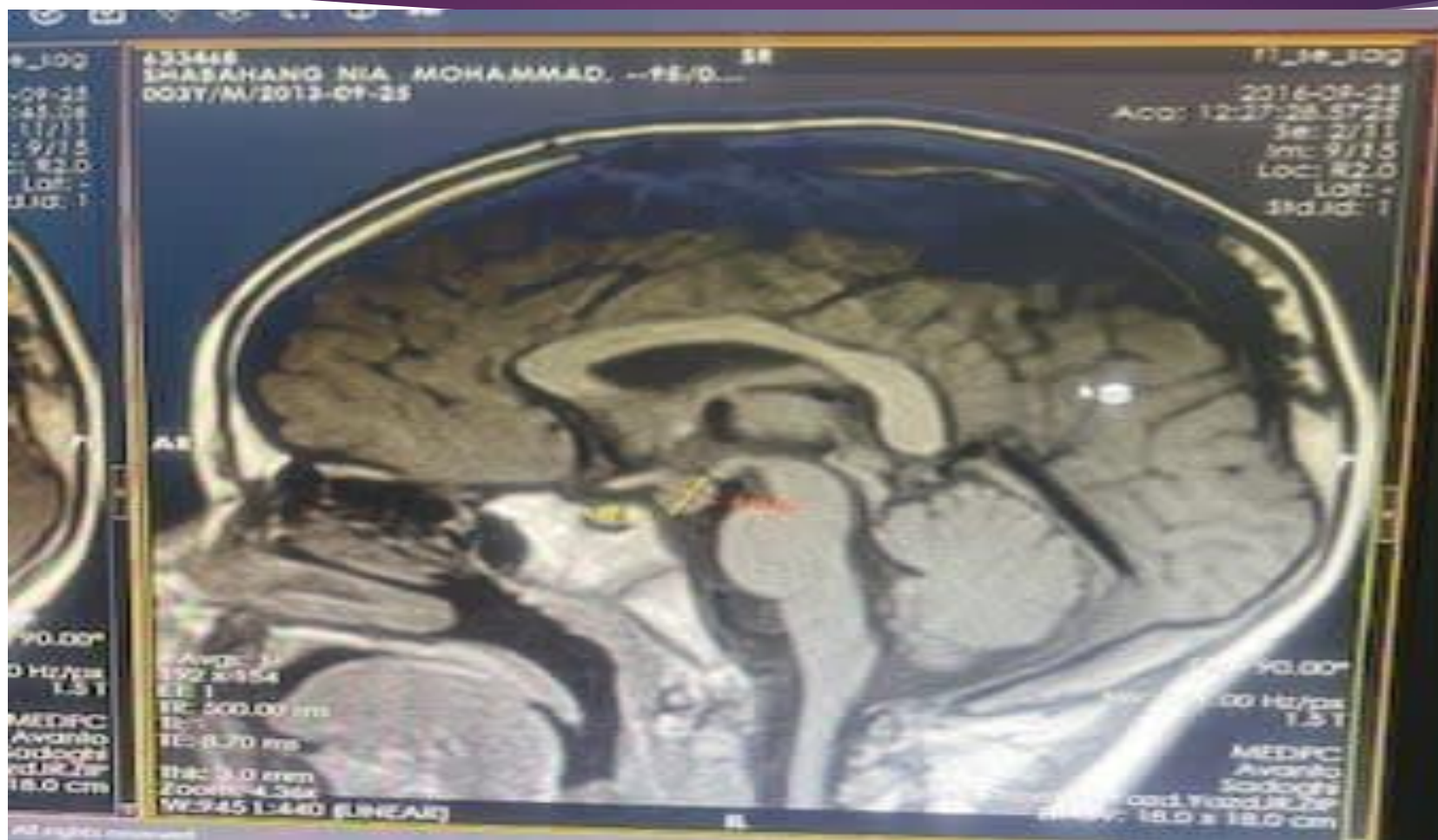
CC:


پسر ۵ ساله با شکایت خنده های کنترل نشده و تغییرات رفتاری

Lab data:

- ▶ Testosterone → upper limit normal
- ▶ LH → upper limit normal
- ▶ FSH → upper limit normal

MRI



- 
- ▶ GnRH agonists (depot forms or implant) are the treatment of choice of tumor-induced CPP. Neurosurgical treatment has been shown to have limited efficacy and to be associated with high complication rates in a subset of patients with hypothalamic hamartoma and associated intractable gelastic or psychomotor seizures. Stereotactic radiation therapy (gamma knife surgery) and, more recently, MRI-guided laser therapy, have been proposed as possible alternatives in these instances

سپاس از حسن توجه شما

